



Date	21 <sup>st</sup> February 2011
Submission To	Podiatry Board of Australia
Title	Feedback and peer review on the consultation paper Blood Borne Infections (due date 25/2/2011)
Prepared by	SA Podiatry Association Council

---

On behalf of the South Australian Podiatry Council we thank the PBA for the opportunity to comment on the draft paper and provide the following feedback.

(?) Missing word

**(Zadek's):** To be correct it is a Zadik's procedure - but given we shouldn't really be using eponyms, perhaps it should be changed to 'total matrixectomy' *Note:* A zadiks's procedure is not an avulsion, it is an avulsion + matrixectomy. Please refer to the attached Zadik's paper for reference.

This policy would probably include podiatrists working in high-risk departments, as there is routinely holes found in feet with bones on view, but maybe not if the criteria as the operators fingers are generally never out of view

#### Exposure-prone procedures by podiatrists

Routine procedures undertaken by ? are not exposure prone. Procedures undertaken by podiatric surgeons include surgery on nails, bones and soft tissue of the foot and lower leg, and joint replacements. In a proportion of these procedures, part of the operator's fingers will be inside the wound and out of view, making them exposure prone procedures.

It should be noted that some nail avulsion procedures, such as **Zadek's** procedure, are considered exposure prone. Chemical matrixectomy is not considered exposure prone because the operator's fingers are not inside tissue during the procedure.

#### *Suggested Text:*

*"It should be noted that some nail procedures, such as total or partial matrixectomy procedures, are considered exposure prone. Chemical matrixectomy is not considered exposure prone because the operator's fingers are not inside tissue during the procedure."*

## OBLITERATION OF THE NAIL BED OF THE GREAT TOE WITHOUT SHORTENING THE TERMINAL PHALANX

F. R. ZADIK, SHEFFIELD, ENGLAND

*From the Wharnccliffe Hospital, Sheffield*

Ingrowing toe nail and onychogryphosis arising from deformity of the nail bed of the great toe often give rise to much disability, and although many treatments have been used none is entirely satisfactory. Conservative measures such as thinning the nail and cutting a longitudinal groove may control the ingrowing, and repeated filing may suffice for onychogryphosis, but such treatment must be continued indefinitely. Repeated avulsion seldom gives permanent cure, and excision of a wedge from the lateral border causes persistent deformity of the nail. Removal of the whole nail bed together with excision of the distal half of the terminal phalanx is often satisfactory but the cosmetic result is poor; the wife of one of my friends who was so treated described her great toes as "two funny little dumplings." Complete excision of the nail bed with mobilisation and suture of the proximal and distal flaps (Nuttall 1941) failed in three cases because tension caused necrosis of the flaps so that the wounds broke down. Moreover excision of the nail bed with skin grafting of the raw area is uncertain.

Excision of all the nail bed is not necessary. Growth of the nail, both in length and thickness, takes place only from the proximal part of the nail bed. The nail bed distal to the lunula makes no contribution and, if growth of the nail over it is prevented, it will assume the characteristics of normal skin (Hermitte 1947). The operation described here is based upon these observations. The purpose is to remove the nail-forming part of the nail bed and provide adequate skin cover without shortening the distal phalanx.

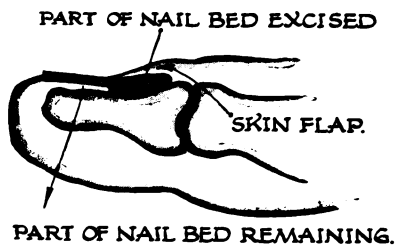


FIG. 1

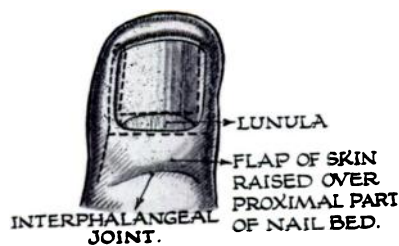


FIG. 2

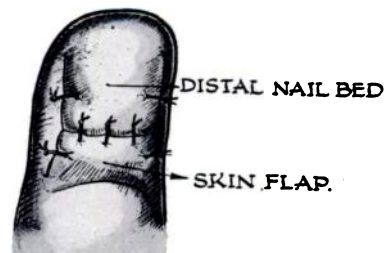


FIG. 3

The skin over the base of the nail bed is raised as a flap (Fig. 1), and the nail is avulsed. The part of the nail bed proximal to the border of the lunula is excised (Fig. 2). The skin flap is advanced and sutured without tension to the cut edge of the distal part of the nail

bed (Fig. 3). If the lateral nail furrows are deep, the lateral nail folds are excised and the skin edges are sutured to the edges of the nail bed.

This operation has been carried out in sixteen cases and the functional and cosmetic results were excellent. In no case was there regrowth of nail; in some there was a little epithelial thickening over the nail bed which was removed easily with a nail brush. In two cases the skin flap was sutured under tension and necrosis of the flap occurred with healing by granulation but this complication should be avoided. If it appears at operation that suture will be possible only under tension it is better to shorten the terminal phalanx. This should also be done if there is a subungual exostosis, or an exaggerated upward curve of the terminal phalanx, because in such cases there would still be shoe pressure against the top of the toe even after removal of the nail bed. When there is infection under the lateral border of the nail, the nail should be avulsed as a first stage and excision deferred for two weeks.

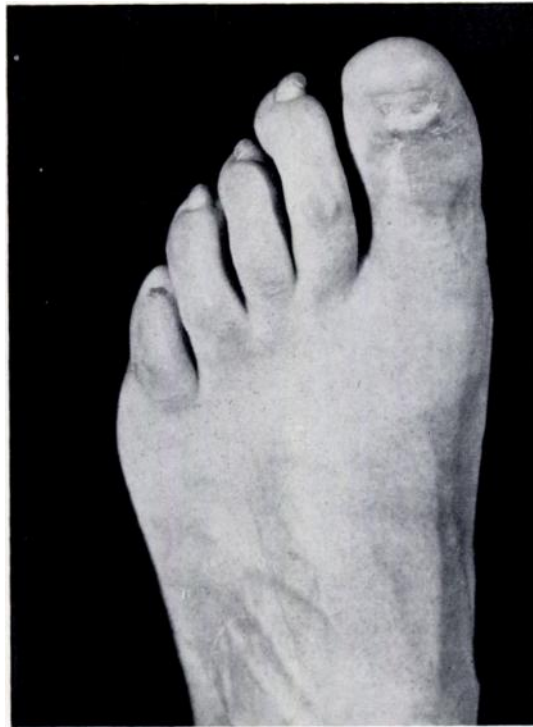


FIG. 4

Result of obliterating nail bed, by the technique described, in a case of onychogryphosis.

The operations were carried out on patients of Mr A. Dornan and Mr F. W. Holdsworth to whom my thanks are due. The figures were drawn by Mr A. S. Foster.

#### REFERENCES

- HERMITTE, G. (1947): Personal communication.  
NUTTALL, H. C. WARDLEWORTH (1941): *Lancet*, **2**, 100.